

Case Report

## ANATOMICAL VARIATION OF THE TRAPEZIUS MUSCLE- A CASE REPORT

Khayati Sant Ram\*, Anjali Aggarwal\*, Tulika Gupta \*, Amandeep kaur\*, Jyoti Rajput\*, Daisy Sahni\*

\*Department of Anatomy, Post Graduate Institute of Medical Education and Research, Chandigarh,

---

### ABSTRACT

During routine cadaveric dissection for undergraduate teaching variation in the course and insertion of fibers left trapezius muscle was noticed in two embalmed male cadavers. Some of the occipital fibers while descending towards clavicle got separated from rest of the muscle, inclined medially and inserted on the 1cm area of middle third of superior surface of clavicle. The remaining occipital fibers got inserted after a gap of on 1.5cm on the superior surface of lateral part of clavicle. Detached portion of trapezius muscles was tendinous in insertion. Two structures namely external jugular vein and supraclavicular nerves were seen passing through the gap in one cadaver (Case 1) whereas in other cadaver (Case 2) only external jugular vein was passing through the gap. Knowledge of this variation is clinically important in surgical exploration of posterior triangle. supraclavicular nerve entrapment syndrome and in various approaches involving external jugular vein.

**Key words:** - trapezius muscle, cleidoccipital, supraclavicular nerves

### INTRODUCTION

Trapezius muscle(TM) is a flat triangular muscle which extends over back of the neck and upper thorax. On either side the muscle is attached to medial third of superior nuchal line, external occipital protuberance, ligamentum nuchae and apices of the spinous processes and their supraspinous ligament from seventh cervical to twelfth thoracic vertebrae. The muscle is inserted classically on posterior border of lateral third of clavicle, medial margin of acromial process and superior lip of crest of spine of scapula. The most commonly reported variations of trapezius muscle in the literature[1] are in the form of its partial or complete absence or even accessory muscle fascicles. These accessory muscular fascicles are mistaken for pathological enlarged lymph nodes, cyst, levator claviculae muscle[2]. They may pose difficulties during exploration of posterior triangle, catheterization of subclavian or internal jugular vein [2, 3].

### CASE REPORT

During routine cadaveric dissection for undergraduate teaching variation in the course and

insertion of clavicular fibers left trapezius muscle of left side was noticed in two adult male cadavers.

Case 1- In 78- years-old male cadaver trapezius muscle of left side took usual origin from the medial portion of superior nuchal line, external occipital protuberance, ligamentum nuchae and apices of the spinous processes of thoracic vertebrae. Some of the occipital fibres while descending towards clavicle got separated from rest of the muscle inclined medially and inserted on the 1 cm area of middle third of superior surface of clavicle. The remaining occipital fibers got inserted on the superior surface of lateral part of clavicle after a gap of on 1.5cm. Detached portion of TM was muscular in insertion. The insertion of muscle on clavicle extended up to 11cm from the lateral end of bone. Total length of clavicle was 19 cm. Thus the muscles occupied more than lateral half of the length of clavicle. External jugular vein passed through this gap to drained into subclavian vein and trunk of supraclavicular nerve emerged out of the gap to become subcutaneous and divided into medial intermediate and lateral supraclavicular nerves.

---

### Address for Correspondence :

Dr. Anjali Aggarwal

Associate Professor

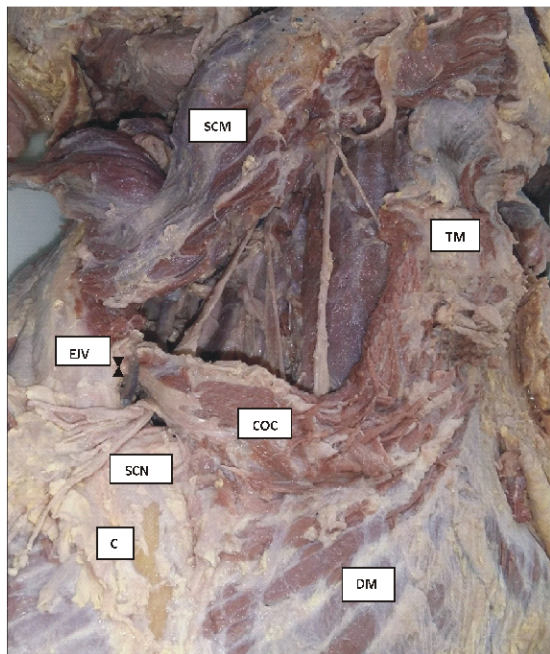
Dept of Anatomy, Post Graduate Institute of Medical Education and Research, Chandigarh, india

Pin code 160012

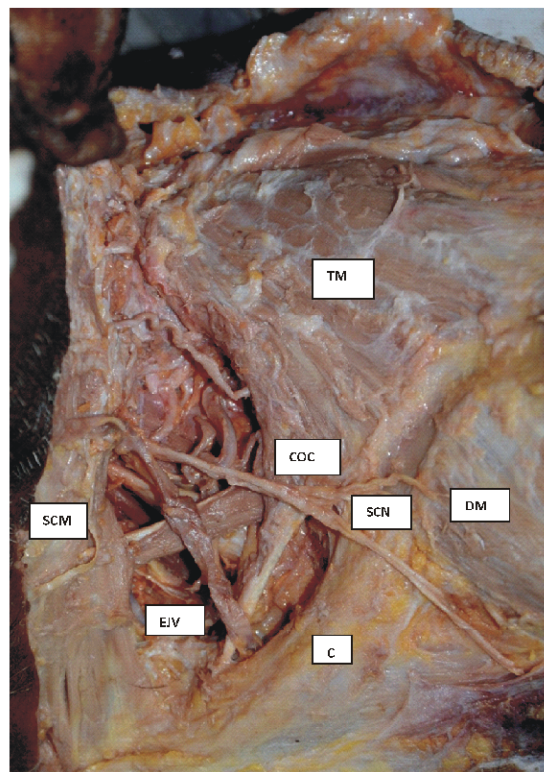
E-mail : khayati\_santram@yahoo.com

Phone No : 8146715466

Fax : 00911722744401



**Fig 1:-CASE 1** Dissection of posterior triangle on left side of neck showing separation of some of the fibers (COC)of trapezius muscle(TM) creating a gap in the muscel.The main muscle the external jugular vein (EJV) and supraclavicular nerves(SCN) are passing through the gap . Abbreviation C- clavicle, DM- Deltoid muscle, SCM -Sternocleidomastoid muscle.



**Fig 2 :-CASE 2** Dissection of posterior triangle on left side of neck showing separation of some of the tendinous fibers (COC) of trapezius muscle(TM) creating a gap. The external jugular vein is (EJV)passing via the gap. Abbreviations used are same as figure 1

Case 2:- After arising normally from superior nuchal line and ligamentum nuchae , clavicular fibers got inserted normally in lateral one third of calvicle. Close to clavicle a tendon appeared from the clavicular fibers of trapzeus muscle of left side. These tendinous fibers coursed parallel to clavicle and got inserted on its posterior surface little way from the clavicle attachément of sternocleidomastoid. This tendon measured 5 cm in length. A triangular gap was present between the main calvicular attachment and acceary tendinous slip of muscle. The muscle fibers of the variant muscle originated from medial part of superior nuchal line. External jugular vein descended on anterior surface of SCM and detached tendinous fibres of trapezius and inclined posteriorly through the gap in the muscle and drained into subclavian vein. The trunk of supraclavicular nerves displayed normal course .

The muscle was supplied by spinal accessory nerve and no additional nerve supply to this accessory slip of muscle was seen. On the right side of both the cases, TM displayed normal extent and course.

## DISCUSSION

Superior occipital portion of trapezius muscle is inserted into posterior border of lateral third of clavicle, middle fibers are inserted on the medial border of acromion and superior lip of scapular spine and inferior fibers on the medial end of scapular spine. Most of variations of trapezius muscle reported in literature are concerned with the extent of its attachments or occasionally partial absence of superior or inferior portion or sometimes the whole muscle[1].

Sometimes some of the clavicular fibres of the muscle separate from the main bulk of muscle leaving a gap in the muscle and and reach the middle portion of calvicle or even blend with SCM. This variant of muscle has been named differently like cleido occipitalis cervicalis muscle and cleido occipitalis[4,5,6]. During routine dissection we found anomalous separation of some of clavicular fibres of left trapezius muscle from rest of the muscle in the neck at the level of hyoid bone associated with supraclavicular nerve and external jugular vein

passing through the gap in trapezius muscle. Similar type of variation has been reported in the past. Patil et al found tendinous fibres separated from the muscle and coursed forward parallel to clavicle and blended with SCM. We found similar variation in one of the case. This separate mass of muscle may be misinterpreted as lymphadenopathy, thrombosed vein, cyst or levator claviculae muscle. Variation in TM may pose difficulties during internal jugular vein or subclavian vein catheterization and supraclavicular fossa exploration[2].

This anomaly in present cases was associated with anomalous course of external jugular vein, supraclavicular nerves passing through the gap. Like our report, Swamy et al found the right external jugular vein passing through the gap in the muscle however unlike our study the external jugular drained into right suprascapular vein. During rotation, retraction and elevation of scapula contraction of the trapezius along with variant muscle may lead to compression of EJV against clavicle. So entrapment of external jugular vein may pose severe clinical complications during radical neck dissection surgeries. External jugular vein is used for various procedures like transjugular liver biopsy, catheterization for hemodialysis[2]. Therefore any variation in external jugular vein should be kept in mind by surgeons, radiologists, plastic surgeon.

The supraclavicular nerve after arising from cervical plexuses in posterior triangle pierce the investing layer of deep cervical fascia and descend superficial to clavicle and supply skin of pectoral region upto level of second rib and skin covering upper half of deltoid[1]. In one of our case the supraclavicular trunk traversed through the gap in the muscle which may result in nerve entrapment syndrome. Parskevas et al[7] found the trunk of supraclavicular nerves in the gap and In this case, record of specimen showed history of pain and sensory disturbances of the ipsilateral upper arm and shoulder were present with presumptive diagnosis of cervical spondylosis. Rahman and Yamadori reported an anomalous insertion of trapezius muscle not associated with variation in external jugular vein and supraclavicular fibres.

As suggested by Rahman et al anomalous separation of muscle fibres could be due separation

from trapezius muscle and sternocleidomastoid muscle anlage [6].

## CONCLUSION

Knowledge of this variation is clinically important in supraclavicular nerve entrapment syndrome and in various therapeutic approaches involving external jugular vein.

No conflict of interest

## Acknowledgement

Authors wish to thank Mr Pardeep Singh for photography

## References

1. Standring S. Grays anatomy .39th ed. Edinburgh: Churchill livingstone, Elsevier; 2004. p.532.
2. Patil J, Souza M, Kumar N, Ravindra S, Aithal. A rare case of tendinous clavicular insertion of trapezius muscle: Could it be a cause for supraclavicular nerve entrapment syndrome? Sifa Med J 2016; 3:28-30.
3. Kwak HH, Kim HJ, Youn KH, Park HD, Chung IH. An anatomical variation of trapezius muscle in a Korean: The cleido-occipitalis cervicalis. Yonsei Med journal 2003; 44: 1098-100.
4. Nagashima S, Yamaki K, Ohkawa T, Humatsu S, Hianuma S. An extremely rare case of M. cleido-cervicalis and M. cleido-occipitalis. JKurumeMedAssoc 1989; 52: 680-7.
5. Tomo S, Toh H, Hirakawa T, Tomo I, Kobayashi S. Case report: The cleidocervical muscle with speculation as to its origin. JAnat 1994; 184:165-9.
6. Rahman HA, Yamadori T. An anomalous cleido-occipitalis muscle. Acta Anat (Basel) 1994; 150:156-8.
7. Parskevas GK, Natsis Kloannidis O. Accessory cleido-occipitalis muscle: case report and review of the literature. Rom J Morphol Embryology 2013, 54(3 suppl):893-895.